

## Economic solutions for primary and total hip arthroplasty revision from the Egyptian experience

Soluciones económicas para la revisión primaria y total de cadera a partir de la experiencia egipcia

Ahmed A. Khalifa<sup>1\*</sup> <https://orcid.org/0000-0002-0710-6487>

Mohamed A. Mahran<sup>2</sup> <https://orcid.org/0000-0003-4475-2506>

Ahmed M. Abdelaal<sup>2</sup> <https://orcid.org/0000-0003-1758-5538>

<sup>1</sup>South Valley University, Faculty of Medicine. Qena, Egypt.

<sup>2</sup>Assiut University Hospital, Orthopaedic and traumatology Department. Assiut, Egypt.

\*Corresponding author: [khalifaahmed8486@yahoo.com](mailto:khalifaahmed8486@yahoo.com)

### ABSTRACT

**Background:** The current review aims to shed light on some economic solutions that Egyptian arthroplasty surgeons employ to facilitate and mitigate the cost issues during primary and revision of total hip arthroplasties (THAs).

**Methods:** A PubMed search was carried out till December 2022 using the following search terms ((arthroplasty) AND (Egypt[Affiliation])) to detect the arthroplasty-related articles published since 1996. The articles which included economic solutions and technical aspects were included; furthermore, the included articles' authors' profiles were searched for other possible published articles.

**Results:** The search revealed 262 articles published during the search period, of which eight were eligible to be included, and a further search of the authors'

profiles revealed two other articles, giving a final ten articles offering economical solutions related to primary and revision THA. Three articles reported the results of impaction bone grafting to reconstruct acetabular bone defects both in primary and revision THA; two discussed smartphone applications for assisting acetabular cup placement during primary THA; two discussed the effectiveness of using homemade cement spacers for infected THAs, two described using cheap tools during revision THA, and the final article reported using usual plates and screws in managing periprosthetic femoral fractures.

**Conclusion:** Egyptian arthroplasty surgeons used some economic solutions which could play a role in facilitating and decreasing the cost of primary and revision THAs without the need for costly tools and technologies. Further aspects of arthroplasty practice should be improved, including establishing registries and improving the research output.

**Keywords:** arthroplasty; developing countries; total hip arthroplasty; economic solutions; Egypt.

## RESUMEN

**Antecedentes:** La presente revisión pretende arrojar luz sobre algunas soluciones económicas que los cirujanos de artroplastia egipcios emplean para facilitar y mitigar los problemas de costes durante las artroplastias totales de cadera (ATC) primarias y de revisión.

**Métodos:** Se realizó una búsqueda en PubMed hasta diciembre de 2022 utilizando los siguientes términos de búsqueda ((arthroplasty) AND (Egypt[Affiliation])) para detectar los artículos relacionados con la artroplastia publicados desde 1996. Se incluyeron los artículos que incluían soluciones económicas y aspectos técnicos; además, se buscó en los perfiles de los autores de los artículos incluidos otros posibles artículos publicados.

**Resultados:** La búsqueda reveló 262 artículos publicados durante el periodo de búsqueda, de los cuales ocho cumplían los requisitos para ser incluidos, y una búsqueda adicional de los perfiles de los autores reveló otros dos artículos, lo que dio un total final de diez artículos que ofrecían soluciones económicas relacionadas con la ATC primaria y de revisión. Tres artículos informaron de los resultados del injerto óseo por impactación para reconstruir defectos óseos acetabulares tanto en la ATC primaria como en la de revisión; dos

hablaron de aplicaciones de teléfonos inteligentes para ayudar a la colocación del cotilo acetabular durante la ATC primaria; dos hablaron de la eficacia del uso de espaciadores de cemento caseros para las ATC infectadas, dos describieron el uso de herramientas baratas durante la ATC de revisión, y el último artículo informó del uso de placas y tornillos habituales en el tratamiento de fracturas femorales periprotésicas.

**Conclusiones:** Los cirujanos de artroplastia egipcios utilizaron algunas soluciones económicas que podrían desempeñar un papel a la hora de facilitar y disminuir el coste de las ATC primarias y de revisión sin necesidad de herramientas y tecnologías costosas. Deberían mejorarse otros aspectos de la práctica de la artroplastia, como el establecimiento de registros y la mejora de los resultados de la investigación.

**Palabras clave:** artroplastia; países en desarrollo; artroplastia total de cadera; soluciones económicas; Egipto.

Recibido: 21/05/2023

Aceptado: 08/07/2023

## Introduction

Total hip arthroplasty (THA) is considered one of the most successful surgeries, which evolved rapidly over the past two decades, aiming to relieve pain and improve function in patients with disabling hip diseases.<sup>(1)</sup> Furthermore, the advancement related to the implant materials and designs and the assistive technology for improving the precision of the surgery was tremendous over the past few years, with a parallel increase in the surgery cost.<sup>(2)</sup>

Countries are being classified according to the development level measured by per capita gross national income into high-income, upper-middle-income, lower-middle-income, and low-income countries; furthermore, the United Nations considered low and middle-income countries as “developing” countries, where Egypt falls in this category.<sup>(3,4)</sup> This classification impacts

countries' ability to improve, support, and introduce newer technologies in their healthcare system, seeking to provide better patient care.

The estimated cost of primary THAs could reach up to \$13,000, which is subjected to even more increases reaching double the costs in cases of revision THA.<sup>(2,5,6,7,8)</sup> The high cost of commercially used medical devices (including THA) poses a challenge to the healthcare system in developing countries.<sup>(9,10)</sup> These costs should be considered when deciding on hip replacement surgery for a patient in a developing country, especially when some patients do not have health coverage.<sup>(2,11)</sup> So, surgeons in developing countries have to resist the temptation of using new costly technologies, and at the same time, they have to improvise to create economical solutions. An example of these solutions was re-using external fixators to manage trauma patients.<sup>(12)</sup> Some authors reported on the "off-label" use of the available resources for fracture fixation to compensate for the logistic deficiencies.<sup>(13)</sup> At the same time, a group of Nigerian surgeons described their experience of treating long bone fractures with intramedullary nails without needing a specialized traction table or image intensifier.<sup>(14)</sup>

Various improvements related to the implants, assistive tools, and peri-operative patient care were introduced during THA surgery to decrease the cost of such surgical procedures.<sup>(2)</sup> The current review aims to shed light on some economic solutions that Egyptian arthroplasty surgeons use to facilitate and mitigate the cost issues during primary and revision THAs. Furthermore, we discussed some of the obstacles and limitations related to the advancement of arthroplasty practice in developing countries.

## Methods

A PubMed search was carried out till December 2022 using the following search terms ((arthroplasty) AND (Egypt [affiliation])) to detect the arthroplasty-related article published since 1996. The articles were screened initially by title and abstract; we excluded irrelevant articles or studies on total knee arthroplasty (TKA). Then a final assessment of the remaining articles was performed by discussion among the authors to include articles discussed or reported economic solutions and technical aspects during primary or revision THA. The last step was to search the authors' personal research profiles

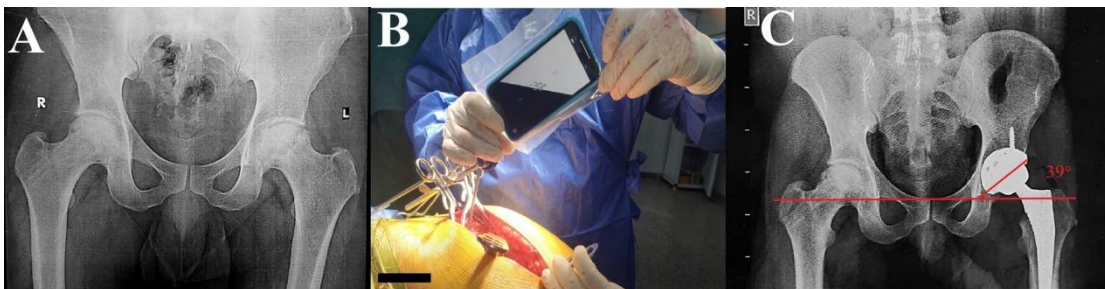
(Google Scholar and ResearchGate) of the included articles, looking for other possible published related articles.

## Results

The search revealed 262 articles; we excluded 254 (90 were irrelevant, and 164 reported either on TKA or studies on THA which did not include the data we were concerned with collecting). Final eight articles were eligible to be included,<sup>(15,16,17,18,19,20,21,22)</sup> and a further search of the authors' profiles revealed two other articles,<sup>(23,24)</sup> giving a final ten articles discussing solutions related to primary and revision THA. The details of the included articles are as follows:

### A - Primary THA

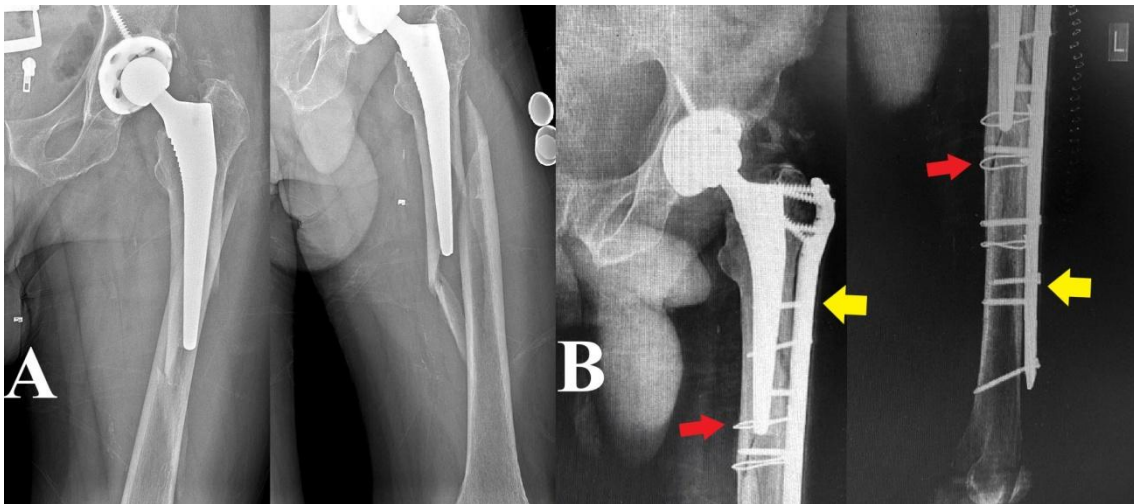
1. Smartphone-assisted acetabular cup placement (fig. 1): In an attempt to properly position the acetabular cup, several authors used smartphone applications intraoperatively after adjustment for the possible pelvis lateral tilt, aiming to place the acetabular cup within the Lewinnek safe zone.<sup>(15,17)</sup>



**Fig. 1** - Using smartphone applications for adjusting cup abduction angle during primary THA. A) Preoperative radiograph of a male patient, 35 years old, having avascular necrosis of the left hip. B) Intraoperative adjustment of the cup abduction angle assisted by an inclinometer application downloaded to a smartphone. C) Postoperative radiograph after implantation of a cementless THA showing proper acetabular cup position.

2. Usual plates and screws for femoral periprosthetic fracture management (fig. 2): A study by *Taha et al*<sup>(16)</sup> reported on managing femoral periprosthetic

fractures after THA by open reduction and internal fixation (ORIF). Although the authors reported that the choice of the implants was according to the surgeon; however, they used conventional trauma locking plates and screws in some of their patients without the need for a specialized periprosthetic fixation system.

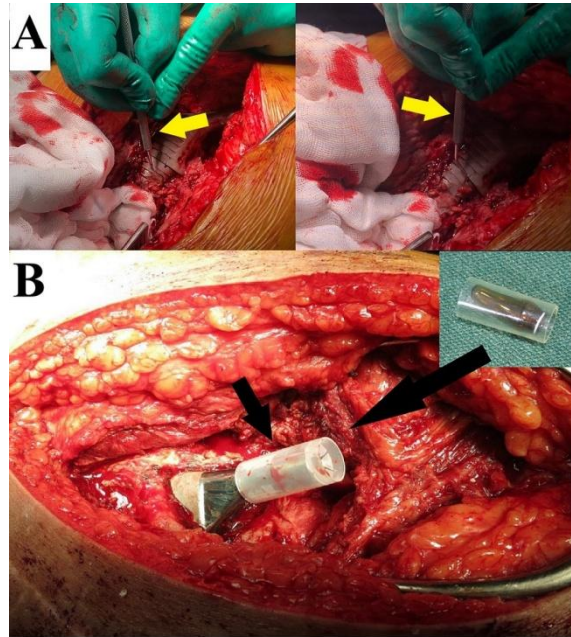


**Fig. 2** - Treating femoral periprosthetic fracture with open reduction and internal fixation (ORIF) using a locked plate and screws. A) Preoperative radiograph of a male patient, 43 years old, who had a traumatic periprosthetic femoral fracture around a cementless femoral stem. B) ORIF was performed using a locked plate and screws (yellow arrows), and cerclage wires were added to supplement fixation (red arrows).

## B - Revision THA

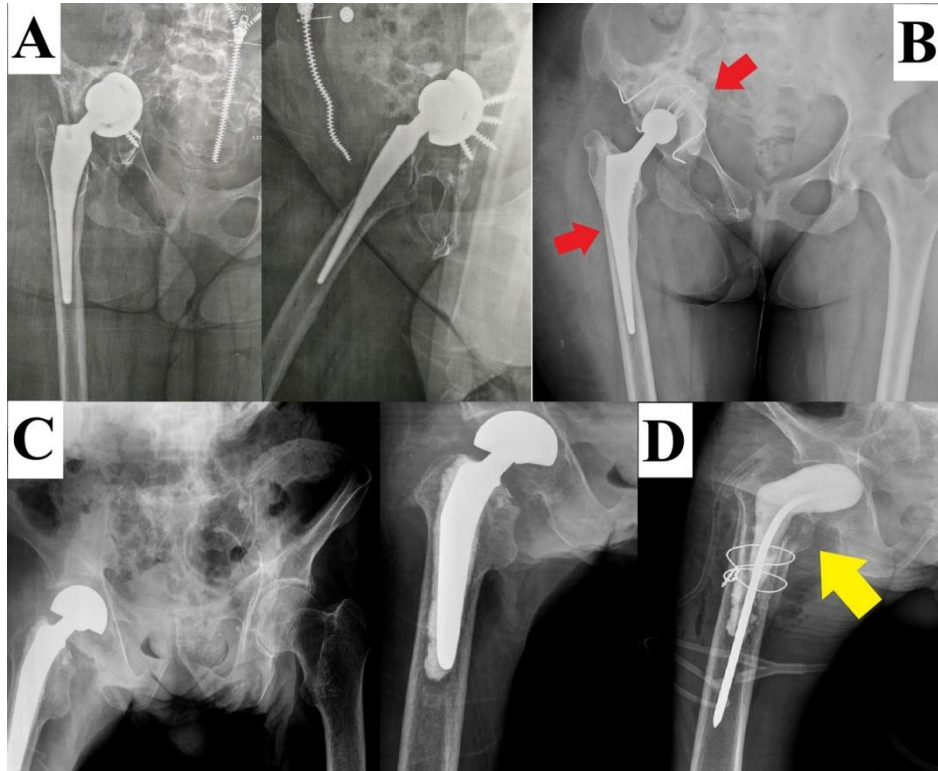
1. Impaction bone grafting (IBG) for acetabular bone defect reconstruction: In a study by *Abdelnasser et al*<sup>(19)</sup> the authors reported the effectiveness of IBG for reconstructing acetabular defects (type I and II according to AAOS classification) in both primary and revision THA patients. *Ebied et al*<sup>(21)</sup> utilized IBG using fresh frozen femoral head allograft loaded with antibiotics to reconstruct acetabular bone defect in 33 patients who underwent a single-stage revision THA for infection. Furthermore, aiming at converting the acetabular defect into a more contained type, *Ebied et al*<sup>(18)</sup> used metal augment to reconstruct a segmental defect in the superior or posterosuperior aspect of the acetabulum, followed by IBG to reconstruct floor and wall defects.

2. Cheap tool to assist implant removal and protection during revision THA surgery (fig. 3): A dental probe as an adjuvant tool during the removal of well-fixed THA implants was proposed by *Khalifa et al*<sup>(23)</sup> Furthermore, as a cheap and affordable technique, a part of a disposable plastic syringe to cover and protect the trunnion during acetabular cup-only THA revision surgery was suggested by *Abdelaal et al.*<sup>(24)</sup>



**Fig. 3** – A) A dental probe is used to work around the interface between a cementless femoral stem and the bone to ease removal. B) A disposable plastic syringe used to cover the femoral stem trunnion while retaining the stem during revision THA.

3. Homemade cement spacers (fig. 4): In a study by *Ebied et al*,<sup>(20)</sup> the authors used homemade antibiotic-loaded cement spacers during the first stage of THA for treating infected nonunion hip fractures. In another study by *El-Ganzoury and Eid*,<sup>(22)</sup> the authors reported fabricating a temporary cement spacer using either an inexpensive modular femoral stem or, in some cases they used the same stem, which was removed from the patient after re-sterilization. At the same time, for the acetabular side, they fashioned the cement acetabular component using the acetabular reamer tray as a mold.



**Fig. 4** - Homemade antibiotic-loaded cement spacers during the first stage of revision THA for infection. A) Preoperative radiograph of a female patient 34 years old with an infected cementless THA associated with central cup migration. B) First stage revision THA by an articulating spacer using the same stem after reesterilization and a fabricated acetabular liner (red arrow). C) Preoperative radiograph of a male patient 75 years old with an infected cemented bipolar prosthesis. D) A homemade articulating cement spacer (yellow arrow).

## Discussion

Undoubtedly, advances in THA implant materials, designs, instruments, and peri-operative care are paramount for improving this procedure's cost-effectiveness; furthermore, there is an added value related to patients' quality of life outcomes improvement and reducing morbidity and mortality incidences.<sup>(22)</sup> However, these advances could be easily adopted in developed countries but hardly implemented in developing countries owing mainly to financial and funding obstacles.<sup>(11,26)</sup>

In the current review, we reported some of the options and solutions used by Egyptian arthroplasty surgeons to mitigate and reduce the cost of primary and



revision THA surgeries. We admit that most solutions are not new, but the authors tried to use these techniques and tactics to overcome some economic burdens besides introducing some new techniques and tools.

Obtaining optimum implant positioning during primary THA is paramount to restoring native hip biomechanics for better function; new technologies were introduced to precisely achieve these aims, such as computer navigation, handheld navigation, and robotic-assisted surgery.<sup>(27,28)</sup> These technologies enable surgeons to obtain the preplanned desired cup inclination, anteversion, center of rotation, and femoral offset and restore leg length equality.<sup>(2)</sup> However, most of these technologies need preoperative CT scan for planning, special intraoperative preparations, trained personnel, and continuous maintenance, which will increase the procedure's cost and economic burden.<sup>(29)</sup> Using smartphone apps during THA, *Khalifa et al.*<sup>(15)</sup> showed that this technique enabled a young, less experienced surgeon to improve the accuracy of cup placement within the safe zone from 63 % with the manual instruments to 93 % after using the smartphone applications. Although the authors did not include the cost analysis of this technique, they reported using a disposable plastic bag and instrument from an external fixator set, which is already present in the operating theater, without the need for special preparations.

Regarding periprosthetic femur fracture, which could complicate primary or revision THA surgeries, the management options could be either ORIF with stem retention or femoral stem revision, depending on factors related to the implant, the nature of the fracture, and the patient status.<sup>(30)</sup> If the option of ORIF was amenable, various fixation devices could be used; with the introduction of contemporary specialized periprosthetic fracture fixation plates, the cost could increase to \$ 26,000.<sup>(31,32)</sup> In a study by *Taha et al.*<sup>(16)</sup> the authors reported accepted functional and radiological outcomes after fracture fixation using the locked plates used in trauma surgery without needing a specialized periprosthetic plate system.

Revision THA poses an economic burden on the healthcare system, which even increases in cases of revision THA after infection or recurrent dislocation.<sup>(8,33)</sup> Revision THA surgery occasionally starts with removing the previous implants, which could be well fixed, and efficient and bone-conserving removal of these implants is paramount, that is why various tools with variable costs are available for implant removal.<sup>(34)</sup> *Khalifa et al.*<sup>(23)</sup> used a dental probe as an adjuvant tool during the removal of well-fixed THA

implants; the authors reported that this tool could only cost up to \$ 10 in their market, which is considered affordable.

Surgeons frequently face variable degrees and severity of acetabular bone defects, which need to be reconstructed to restore the hip joint center of rotation for optimum outcomes.<sup>(35)</sup> Various strategies and implants were proposed for acetabular defect reconstruction, including jumbo cups, oblong cups, anti-protrusion cages, and tantalum metal augment.<sup>(36)</sup> However, using bone grafts (structural allografts or impaction grafting) still represents a considerably cheap and biological way of defect reconstruction.<sup>(37)</sup> *Ebied et al*,<sup>(21)</sup> after an average of six years, follow up reported a success rate (no infection) in 96 % of the cases where IBG was used with antibiotics to reconstruct defects in single-stage revision after infection. Furthermore, using IBG in combination with metal augments helped the authors to avoid using more than one metal augment or specialized reconstructive implants.<sup>(18)</sup> Both techniques utilized in the previous two studies (single-stage revision using antibiotic-loaded IBG and a combination of IBG with metal augments) helped decrease the surgery cost by decreasing hospital admission (as in cases requiring two-stage revision) using fewer metal augments for defect reconstruction.

Retention of a well-fixed femoral stem during one stage revision THA in cases with chronic infection is effective and showed acceptable mid-term outcomes;<sup>(38)</sup> however, for optimum outcomes, a generous approach should be used, and the femoral stem trunnion should be protected throughout the surgery to avoid scratching or damage by retractors or instruments.<sup>(39)</sup> As a cheap and affordable technique to protect the femoral stem trunnion during acetabular cup-only revision, *Abdelaal and Khalifa*<sup>(24)</sup> used a part of a disposable plastic syringe to cover and protect the trunnion during revision surgery.

For an infected THA, revision in two stages is considered the gold standard technique among most arthroplasty surgeons, where the first stage entails implant removal, debridement, and the application of a temporary cement spacer loaded by antibiotics (which could be articulating or non-articulating).<sup>(40)</sup> After infection eradication, the patient could have the second stage, where the final THA prosthesis is implanted. During the first stage, the cement spacer used could be either homemade or prefabricated.<sup>(41)</sup> *Ebied et al*<sup>(20)</sup> reported the effectiveness of using their homemade spacers and the clearance of infection in all patients who completed the treatment protocol.

While in the study by *El-Ganzoury and Eid*,<sup>(22)</sup> the authors reported a 90 % success rate after implementing their technique. In a study by *Moerenhout et al*<sup>(42)</sup> comparing the cost of homemade or prefabricated cement spacers, the authors reported that the homemade spacers are 40 to 50 % cheaper than the prefabricated ones. Using a homemade spacer enables the surgeon to add further antibiotics different from what is already mixed with the cement, and it offers cost savings in an already highly costly surgery.<sup>(42,43)</sup>

Further issues made developing countries different regarding their arthroplasty practice and should be considered when searching for solutions to make THA surgery more efficient and cost-effective. First, patients demographics and indication for surgeries are considerably different in developing countries compared to developed countries, as younger patients with a mean age ranging between 41 to 59 are being operated upon in developing countries,<sup>(44,45)</sup> compared to a mean age between 65 to 70 years in developed countries.<sup>(46)</sup>

Second, maintaining a constant implant supply. In countries passing by an economic crisis, the implants supplying companies become reluctant to offer enough implants to suffice the market's need for fear of not being compensated well.<sup>(46)</sup> Furthermore, most financial resources in developing countries are targeted mainly toward infectious and communicable diseases rather than joint replacement surgeries.<sup>(46,47)</sup>

Third, sterilization issues. Operating room sterility is directly correlated to surgical site infections, and most guidelines developed for preventing infections are produced in organizations based in developed countries. Sometimes, these recommendations could not be easily applied in developed countries.<sup>(46,48)</sup>

Fourth, arthroplasty registries are well established in developed countries, the data of which help in the assessment and improving the outcomes of total joint arthroplasty surgeries. Lack of registry and deficiency in documentation in developing countries is another obstacle in the way to improving the total joint arthroplasty practice. Registry data are essential for comparing different outcomes, tracking implant behavior, and detecting early failures.<sup>(49,50)</sup>

Fifth, musculoskeletal research productivity is another area of improvement in developing countries, owing to low financial investment and funding, which hinders generous research activities.<sup>(51)</sup> Fund and financial support allocation in developing countries are toward managing infectious diseases.<sup>(10,52)</sup> As not

all developing countries can afford the utilization of newer and more costly technologies, Further research production is needed from the developing world to offer economical and straightforward solutions.<sup>(51,53)</sup>

Last, when discussing the developing world surgical care efficiency, although training overseas and getting experience from developed countries' surgical centers will impost the surgical practice in developing countries, only some solutions, preparations, and facilities will be available back home. So, a surgeon in training should learn how to accommodate these advancements and pick what would work with the limited resources at their institutions; furthermore, books written by authors from developed countries should allude to the common problems encountered in developing countries, and a balance should be present between developing countries needs and the recent technologies and advances.<sup>(54)</sup>

Although we tried only to describe and shed some light on the possible economic solution still being practiced and utilized by Egyptian arthroplasty surgeons to overcome the economic burden without further analysis of other details related to these solutions, we admit that the current review has some inherent limitations. First, this review lacks the robustness of systematic reviews and metanalysis in some aspects, such as searching only one database, which could deprive other articles of being included, and the higher possibility for selection bias. Second, we should have discussed different outcomes reported in the included articles. Third, some of the presented ideas and techniques are not novel; however, they are still being utilized due to the unavailability of other alternatives and their low cost. Last, we should have included a detailed cost analysis comparing the techniques presented in the current review and the other alternative offered by other surgical groups from different centers worldwide, however, this was difficult due to the unavailability of cost evaluation in the articles included for formulation of the current review.

## Conclusion

As the old saying "necessity is the mother of invention." Egyptian arthroplasty surgeons are still using some well-known economic solutions besides introducing further techniques and ideas which could play a role in facilitating the primary and revision THAs without the need for costly tools and

technologies. Further aspects of arthroplasty practice should be improved, including establishing registries, improving the peri-operative circumstances, providing detailed cost analysis of these procedures, and increasing the research output.

## References

1. Bombah FM, Lekina FA, Nguiabanda L, Dakoure PWH, Sermon A. Use of dual mobility cups for total hip arthroplasty in sub-Saharan Africa: interest and perspectives. *Int Orthop.* 2022;46(1):133-42. DOI: <https://doi.org/10.1007/s00264-021-05184-1>
2. Fontalis A, Epinette JA, Thaler M, Zagra L, Khanduja V, Haddad FS. Advances and innovations in total hip arthroplasty. *SICOT J.* 2021;7:26. DOI: <https://doi.org/10.1051/sicotj/2021025>
3. Kaplan WA, Ritz LS, Vitello M. Local production of medical technologies and its effect on access in low and middle income countries: a systematic review of the literature. *South Med Rev.* 2011;4(2):51-61. DOI: <https://doi.org/10.5655/smr.v4i2.1002>
4. Turner J, Duffy S. Orthopaedic and trauma care in low-resource settings: the burden and its challenges. *Int Orthop.* 2022;46(1):143-52. DOI: <https://doi.org/10.1007/s00264-021-05236-6>
5. Lisenda L, Mokete L, Mkubwa J, Lukhele M. Inpatient mortality after elective primary total hip and knee joint arthroplasty in Botswana. *Int Orthop.* 2016;40(12):2453-8. DOI: <https://doi.org/10.1007/s00264-016-3280-6>
6. Zomar BO, Marsh JD, Bryant DM, Lanting BA. The cost of outpatient versus inpatient total hip arthroplasty: a randomized trial. *Can J Surg.* 2022;65(5):E553-61. DOI: <https://doi.org/10.1503/cjs.003821>
7. Robinson JC, Pozen A, Tseng S, Bozic KJ. Variability in costs associated with total hip and knee replacement implants. *J Bone Joint Surg Am.* 2012;94(18):1693-8. DOI: <https://doi.org/10.2106/jbjs.k.00355>
8. Kurtz SM, Higgs GB, Lau E, Iorio RR, Courtney PM, Parvizi J. Hospital costs for unsuccessful two-stage revisions for periprosthetic joint infection. *J*

Arthroplasty. 2022;37(2):205-12. DOI:  
<https://doi.org/10.1016/j.arth.2021.10.018>

9. Kouassi KJ, Cartiaux O, Fonkoue L, Detrembleur C, Cornu O. Biomechanical study of a low-cost external fixator for diaphyseal fractures of long bones. *J Orthop Surg Res.* 2020;15(1):247. DOI: <https://doi.org/10.1186/s13018-020-01777-5>

10. Cinthuja P, Wijesinghe PCI, Silva P. Use of external fixators in developing countries: a short socioeconomic analysis. *Cost Eff Resour Alloc.* 2022;20(1):14. DOI: <https://doi.org/10.1186/s12962-022-00353-4>

11. Dossche L, Noyez JF, Ouedraogo W, Kalmogho E. Establishment of a hip replacement project in a district hospital in Burkina Faso: analysis of technical problems and peri-operative complications. *Bone Joint J.* 2014;96-B(2):177-80. DOI: <https://doi.org/10.1302/0301-620x.96b2.31304>

12. Padhi NR, Padhi P. Use of external fixators for open tibial injuries in the rural third world: panacea of the poor? *Injury.* 2007;38(2):150-9. DOI: <https://doi.org/10.1016/j.injury.2006.08.053>

13. Wichlas F, Hofmann V, Strada G, Moursy M, Deininger C. Off-label use of orthopedical trauma implants in a low-income country. *Int Orthop.* 2022;46(1):21-7. DOI: <https://doi.org/10.1007/s00264-021-04990-x>

14. Adesina SA, Eyasan SU, Amole IO, Awotunde OT, Akinwumi AI, Durodola AO, *et al.* Closed reduction and locked intramedullary nailing of diaphyseal long bone fractures without intra-operative imaging and fracture table. *Int Orthop.* 2022;46(1):51-9. DOI: <https://doi.org/10.1007/s00264-021-05091-5>

15. Khalifa AA, Abdelnasser MK, Ahmed AM, Shetty GM, Abdelaal AM. Smartphone application helps improve the accuracy of cup placement by young, less-experienced surgeons during primary total hip arthroplasty. *Arch Bone Jt Surg.* 2022;10(3):278-85. DOI: <https://doi.org/10.22038/abjs.2021.52402.2587>

16. Taha A, ElZaher EH, ElGanzoury I, Ashoub M, Khairy A. Osteosynthesis and outcomes of traumatic periprosthetic femoral fractures after total hip arthroplasty. *Arthroplasty.* 2021;3(1):31. DOI: <https://doi.org/10.1186/s42836-021-00089-1>

17. Khalifa AA, Bakr HM, Said E, Mahran MA. Technical note on using intraoperative smartphone applications to adjust cup inclination angle during

total hip arthroplasty (THA). Arch Bone Jt Surg. 2020;8(6):734-8. DOI: <https://doi.org/10.22038/abjs.2020.44466.2217>

18. Ebied AM, Ebied AA, Marei S, Smith E. Enhancing biology and providing structural support for acetabular reconstruction in single-stage revision for infection. J Orthop Traumatol. 2019;20(1):23. DOI: <https://doi.org/10.1186/s10195-019-0530-6>

19. Abdelnasser MK, Khalifa AA, Mahran MA, Mosa M, Bakr HM, Khalifa YE, *et al.* Post-operative hip centre restoration and migration after impaction bone grafting in revision and complex primary hip arthroplasty. Eur J Orthop Surg Traumatol. 2019;29(7):1411-7. DOI: <https://doi.org/10.1007/s00590-019-02458-8>

20. Ebied AM, Elseedy AI, Gamal O. A protocol for staged arthroplasty to salvage infected nonunion of hip fractures. J Orthop Traumatol. 2017;18(1):43-50. DOI: <https://doi.org/10.1007/s10195-016-0419-6>

21. Ebied AM, Elseedy AI, Gamal O. Single-stage revision for periprosthetic hip infection using antibiotic loaded impaction graft. Hip Int. 2016;26(6):573-9. DOI: <https://doi.org/10.5301/hipint.5000401>

22. El-Ganzoury I, Eid AS. Two-stage arthroplasty using functional temporary prosthesis to treat infected arthroplasty and septic arthritis of the hip. J Orthop. 2015;12(suppl 1):S86-93. DOI: <https://doi.org/10.1016/j.jor.2014.04.006>

23. Khalifa AA, Abdelaal AM, Moustafa MMA, Mahran MA. A humble periodontal probe can help implant removal during revision total joint arthroplasty: a technical note. Techn Orthop. 2022;37(4):283-4. DOI: <https://doi.org/10.1097/BTO.0000000000000590>

24. Abdelaal AM, Khalifa AA. A disposable plastic syringe helps protect the femoral stem trunnion during acetabular cup only revision: A technical note. J Musculoskelet Surg Res. 2023;7:49-51. DOI: [https://doi.org/10.25259/JMSR\\_134\\_2022](https://doi.org/10.25259/JMSR_134_2022)

25. Higashi H, Barendregt JJ. Cost-effectiveness of total hip and knee replacements for the Australian population with osteoarthritis: discrete-event simulation model. PLoS One. 2011;6(9):e25403. DOI: <https://doi.org/10.1371/journal.pone.0025403>

26. Lisenda L, Mokete L, Nwokeyi K, Gureja YP, Lukhele M. Development of a lower limb arthroplasty service in a developing country: Lessons learned after the first 100 cases (joints). *Acta Orthop Belg.* 2016 [access 05/01/2023];82(3):570-8. Available at: <https://www.ncbi.nlm.nih.gov/pubmed/29119899>
27. Kolodychuk NL, Raszewski JA, Gladnick BP, Kitziger KJ, Peters PC, Waddell BS. Handheld navigation improves accuracy in direct anterior total hip replacement. *Arthroplast Today.* 2022;17:58-65. DOI: <https://doi.org/10.1016/j.artd.2022.06.016>
28. Karunaratne S, Duan M, Pappas E, Fritsch B, Boyle R, Gupta S, *et al.* The effectiveness of robotic hip and knee arthroplasty on patient-reported outcomes: A systematic review and meta-analysis. *Int Orthop.* 2019;43(6):1283-95. DOI: <https://doi.org/10.1007/s00264-018-4140-3>
29. Kirchner GJ, Lieber AM, Haislup B, Kerbel YE, Moretti VM. The cost of robot-assisted total hip arthroplasty: comparing safety and hospital charges to conventional total hip arthroplasty. *J Am Acad Orthop Surg.* 2021;29(14):609-15. DOI: <https://doi.org/10.5435/jaaos-d-20-00715>
30. Sidler-Maier CC, Waddell JP. Incidence and predisposing factors of periprosthetic proximal femoral fractures: a literature review. *Int Orthop.* 2015;39(9):1673-82. DOI: <https://doi.org/10.1007/s00264-015-2721-y>
31. Ragland K, Reif R, Karim S, Sexton KW, Cherney SM, Stambough JB, *et al.* Demographics, treatment, and cost of periprosthetic femur fractures: fixation versus revision. *Geriatr Orthop Surg Rehabil.* 2020;11:2151459320939550. DOI: <https://doi.org/10.1177/2151459320939550>
32. Jain S, Menon D, Sheik S, Bennett D, Mitchell T, Kerr J, *et al.* A cost analysis of treating postoperative periprosthetic femoral fractures following hip arthroplasty in a uk tertiary referral centre. *Orthop Proceed.* 2022;104-B(supl 4):3. DOI: <https://doi.org/10.1302/1358-992x.2022.4.003>
33. Schwartz AM, Farley KX, Guild GN, Bradbury TL. Projections and epidemiology of revision hip and knee arthroplasty in the United States to 2030. *J Arthroplasty.* 2020;35(6S):S79-85. DOI: <https://doi.org/10.1016/j.arth.2020.02.030>



34. Masri BA, Mitchell PA, Duncan CP. Removal of solidly fixed implants during revision hip and knee arthroplasty. *J Am Acad Orthop Surg.* 2005;13(1):18-27. DOI: <https://doi.org/10.5435/00124635-200501000-00004>
35. Xiao Q, Xu B, Zhou K, Ling T, Yuan M, Pei F, *et al.* Long-term results of combined porous tantalum augments and titanium-coated cups for Paprosky type III bone defects in acetabular revision. *Int Orthop.* 2021;45(7):1699-706. DOI: <https://doi.org/10.1007/s00264-021-05075-5>
36. Tikhilov RM, Dzhavadov AA, Demin AS, Bilyk SS, Denisov AO, Shubnyakov II. Early outcomes of using custom-made augments in revision total hip arthroplasty. *Int Orthop.* 2022;46(10):2229-35. DOI: <https://doi.org/10.1007/s00264-022-05489-9>
37. Gore DR. Impaction bone grafting for total hip revision. *Int Orthop.* 2002;26(3):162-5. DOI: <https://doi.org/10.1007/s00264-002-0339-3>
38. Ji B, Xu B, Guo W, Rehei A, Mu W, Yang D, *et al.* Retention of the well-fixed implant in the single-stage exchange for chronic infected total hip arthroplasty: an average of five years of follow-up. *Int Orthop.* 2017;41(5):901-9. DOI: <https://doi.org/10.1007/s00264-016-3291-3>
39. Kawalkar AC, Vertzyas N, Neil MJ. Protection of the femoral trunnion during acetabular revision hip surgery-a novel technique. *Arthroplast Today.* 2020;6(4):911-3. DOI: <https://doi.org/10.1016/j.artd.2020.09.015>
40. Gramlich Y, Hagebusch P, Faul P, Klug A, Walter G, Hoffmann R. Two-stage hip revision arthroplasty for periprosthetic joint infection without the use of spacer or cemented implants. *Int Orthop.* 2019;43(11):2457-66. DOI: <https://doi.org/10.1007/s00264-019-04297-y>
41. Kent M, Rachha R, Sood M. A technique for the fabrication of a reinforced moulded articulating cement spacer in two-stage revision total hip arthroplasty. *Int Orthop.* 2010;34(7):949-53. DOI: <https://doi.org/10.1007/s00264-009-0847-5>
42. Moerenhout K, Steinmetz S, Vautrin M, Picarra S, Udin G, Borens O. Economic advantage of 'self-made' antibiotic-loaded spacer compared to prefabricated antibiotic-loaded spacer and spacer molds in two-staged revision arthroplasty. *Acta Orthop Belg.* 2021 [access 05/01/2023];87(3):557-62. Available at: <https://www.ncbi.nlm.nih.gov/pubmed/34808733>

43. Fischbacher A, Peltier K, Borens O. Economic Analysis in a diagnosis related groups system for two-stage exchange of prosthetic-joint infections. *J Bone Jt Infect.* 2018;3(5):249-54. DOI: <https://doi.org/10.7150/jbji.26146>
44. Sambo BT, Allode SA, Ouorou G, Seto DM, Hodonou MA, Romeo H. Total hip arthroplasty in a developin country: epidemiological, clinical and etiological aspects and indications. *J Surg.* 2017;5(6):130-3. DOI: <https://doi.org/10.11648/j.js.20170506.18>
45. Mulla Y, Munthali J, Makasa E, Kayumba K. Joint replacement in Zambia: a review of hip & knee replacement surgery done at the Zambian-Italian Orthopaedic Hospital. *Med J Zambia.* 2010 [access 05/01/2023];37(3):153-9. Available at: <https://www.ajol.info/index.php/mjz/article/view/76412>
46. Pedneault C, St George S, Masri BA. Challenges to implementing total joint replacement programs in developing countries. *Orthop Clin North Am.* 2020;51(2):131-9. DOI: <https://doi.org/10.1016/j.ocl.2019.11.001>
47. Mulimba J. Is hip arthroplasty viable in a developing African country? *East Centr Afri J Surg.* 2007 [access 05/01/2023];12(1):30-2. Available at: <https://www.ajol.info/index.php/ecaajs/article/view/136884>
48. Davies PS, Graham SM, Maqungo S, Harrison WJ. Total joint replacement in sub-Saharan Africa: a systematic review. *Trop Doct.* 2019;49(2):120-8. DOI: <https://doi.org/10.1177/0049475518822239>
49. Delaunay C. Registries in orthopaedics. *Orthop Traumatol Surg Res.* 2015;101(1 suppl):S69-75. DOI: <https://doi.org/10.1016/j.otsr.2014.06.029>
50. Hughes RE, Batra A, Hallstrom BR. Arthroplasty registries around the world: valuable sources of hip implant revision risk data. *Curr Rev Musculoskelet Med.* 2017;10(2):240-52. DOI: <https://doi.org/10.1007/s12178-017-9408-5>
51. Aluede EE, Phillips J, Bleyer J, Jergesen HE, Coughlin R. Representation of developing countries in orthopaedic journals: a survey of four influential orthopaedic journals. *Clin Orthop Relat Res.* 2012;470(8):2313-8. DOI: <https://doi.org/10.1007/s11999-012-2377-5>
52. Luna F, Luyckx VA. Why have non-communicable diseases been left behind? *Asian Bioeth Rev.* 2020;12(1):5-25. DOI: <https://doi.org/10.1007/s41649-020-00112-8>

53. Beveridge M, Howard A. The burden of orthopaedic disease in developing countries. *J Bone Joint Surg Am.* 2004;86(8):1819-22. DOI: <https://doi.org/10.2106/00004623-200408000-00029>

54. Jain AK. Orthopedic services and training at a crossroads in developing countries. *Indian J Orthop.* 2007;41(3):177-9. DOI: <https://doi.org/10.4103/0019-5413.33677>

### **Conflict of interest**

The authors declare that there is no conflict of interest.